

A case of recurrent takotsubo-like cardiomyopathy associated with pheochromocytoma exhibiting different patterns of left ventricular wall motion abnormality and coronary vasospasm: a case report

Koichi Sato¹, Jun Takahashi¹, Keiko Amano ², and Hiroaki Shimokawa ^{1*}

¹Department of Cardiovascular Medicine, Tohoku University Graduate School of Medicine, 1-1 Seiryomachi, Aoba-ku, Sendai 980-8574, Japan; and ²Seifuusou Hospital, 1-9-28 Horinouchi, Niiza 352-0023, Japan

Received 30 December 2019; first decision 3 February 2020; accepted 29 April 2020; online publish-ahead-of-print 25 May 2020

Background

Takotsubo-like cardiomyopathy associated with pheochromocytoma (Pheo-TTS) is a recognized but uncommon disorder. While Pheo-TTS might more often recur and the pattern of left ventricular (LV) wall motion abnormality is more diverse compared with primary TTS, it remains to be elucidated whether coronary functional abnormalities are also involved.

Case summary

A 50-year-old woman was referred with a chief complaint of transient chest pain, dyspnoea, and paroxysmal thyroid swelling that usually developed after meals. In the past, she had been admitted to emergency rooms three times due to pulmonary oedema following the above attacks. Serial cardiac catheterizations showed normal coronary arteries and morphologically different types of LV dysfunction each time; apical LV ballooning at the first, basal LV ballooning at the second, and diffuse LV hypokinesis at the last admission. Acetylcholine (ACh) provocation testing for coronary vasospasm was negative at the second admission. During hospitalization in our department, abdominal ultrasonography for screening detected a right adrenal mass and the urinary normetanephrine level was increased. The adrenal tumour was urgently removed surgically and finally she was diagnosed as having norepinephrine-secreting pheochromocytoma. Acetylcholine testing was again performed just after the operation, showing both epicardial and microvascular coronary spasms. Since the operation, she has been free of symptoms. Importantly, ACh testing at 1-year follow-up showed that epicardial spasm was no longer noted, whereas coronary microvascular spasm persisted.

Discussion

Adrenal pheochromocytoma could cause recurrent attacks of catecholamine surges with different patterns of LV dysfunction, where coronary vasospasm may also be involved along the coronary arteries.

Keywords

Case report • Takotsubo-like cardiomyopathy • Pheochromocytoma • Coronary vasospasm

* Corresponding author. Tel: +81 22 717 7153, Fax: +81 22 717 7156, Email: shimo@cardio.med.tohoku.ac.jp

Handling Editor: Domenico D'Amario

Peer-reviewers: Luca Arcari, Luca Moderato, and Ivan Illic

Compliance Editor: Max Sayers

Supplementary Material Editor: Vassilios Parisi Memtsas

© The Author(s) 2020. Published by Oxford University Press on behalf of the European Society of Cardiology.

This is an Open Access article distributed under the terms of the Creative Commons Attribution Non-Commercial License (<http://creativecommons.org/licenses/by-nc/4.0/>), which permits non-commercial re-use, distribution, and reproduction in any medium, provided the original work is properly cited. For commercial re-use, please contact journals.permissions@oup.com

Learning points

- Catecholamine surges due to pheochromocytoma could cause morphologically different types of transient left ventricular wall motion abnormality and coronary vasospasm.
- Even 1.5 years after removal of pheochromocytoma, microvascular spasm persisted, whereas epicardial coronary spasm disappeared.

Introduction

Stress-induced cardiomyopathy representing as takotsubo syndrome (TTS) is characterized by a striking left ventricular (LV) wall motion abnormality that extends beyond the coronary artery territory with a resultant conspicuous LV ballooning during systole.¹ Although its underlying pathophysiology remains uncertain, it has been widely accepted that stress-related neurohormonal factors, especially catecholamines, play important roles in the pathogenesis. Pheochromocytoma is a catecholamine-producing tumour derived from chromaffin tissue of the sympathetic nerves² and a number of cases of pheochromocytoma-induced TTS (Pheo-TTS) have been reported in the past.³ These case reports revealed that as compared with primary TTS, Pheo-TTS is characterized by a higher prevalence of complications and a higher incidence of apical sparing or global patterns of LV wall motion abnormality.⁴ Accumulating evidence has indicated that coronary functional abnormalities caused by sympathetic nerve activation may also be involved in the pathogenesis of TTS.^{5,6} However, it remains to be elucidated whether repeated and drastic changes in catecholamine levels, which often occur in the clinical course of patients with pheochromocytoma, impact on their coronary vasomotor function. Here, we report a case of Pheo-TTS with different patterns of LV wall motion abnormality, in whom fluctuation of coronary vasomotor abnormality was documented.

Timeline

neck swelling irrespective of emotional stress for ~15 years (Figure 1A). Since the attacks often developed after meals, especially at full stomach, she took care not to eat too much. At the age of 44, she was admitted to the emergency department for the first time due to acute pulmonary oedema following the aforementioned attacks. Urgent cardiac catheterization showed no significant coronary stenosis and typical apical LV ballooning (Figure 2A), and finally she was diagnosed as having TTS. Later, at the age of 45 and 49, she developed the same clinical disorder. Interestingly, the LV wall motion abnormality was localized to the basal region at the second admission (Figure 2B) and diffusely at the last time (no images available). Moreover, during the second admission, acetylcholine (ACh) provocation testing for coronary spasm was performed with negative results. Although local LV asynergy disappeared spontaneously in each hospitalization, she had frequently suffered from the same attacks after meals and was referred to our hospital for further investigation. She did not have any oral medication during the TTS episodes. On admission, she had no subjective symptoms or objective signs in electrocardiogram (ECG) or echocardiographic examinations. However, abdominal ultrasonography for screening purposes detected a right adrenal mass of 35 mm × 35 mm in size and scintigraphy imaging showed high uptake of M-iodobenzylguanidine in the tumour (Figure 1B). Furthermore, urinary catecholamine levels (especially normetanephrine) were markedly elevated (Table 1). Since pheochromocytoma was highly suspected from these data, we paid attention not to perform any contrast studies that could cause

Age	Events
35 years	This patient often presented with transient chest pain, dyspnoea, and paroxysmal neck swelling after meals irrespective of emotional stress
44 years	She developed takotsubo syndrome (TTS) with apical ballooning
45 years	She developed TTS for the second time with basal ballooning. Acetylcholine (ACh) provocation testing was negative
49 years	She developed TTS for the third time with left ventricular diffuse hypokinesia
50 years	She was hospitalized to our institute for further examinations. Abdominal ultrasonography for screening revealed the presence of a right adrenal tumour, which was urgently removed surgically. She was finally diagnosed with norepinephrine-secreting pheochromocytoma
10 days after the operation	ACh provocation testing induced both coronary epicardial and microvascular spasms (MVSs)
1.5 years after the operation	ACh provocation testing induced only coronary MVS but not epicardial coronary spasm

Case presentation

A 50-year-old woman with no coronary artery disease risk factors had suffered from transient chest pain, dyspnoea, and paroxysmal

adrenal crisis. This tumour was urgently removed surgically and histological diagnosis of norepinephrine-secreting pheochromocytoma was made (Figure 1C). Ten days after the operation, when urinary catecholamine levels were normalized (Table 1), we performed cardiac catheterization and ACh provocation testing. As

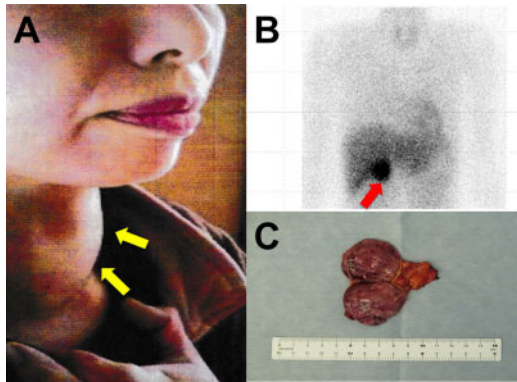


Figure 1 (A) Paroxysmal thyroid swelling (yellow arrows). (B) High uptake of M-iodobenzylguanidine at the right adrenal gland (red arrows). (C) Surgically resected adrenal tumour.

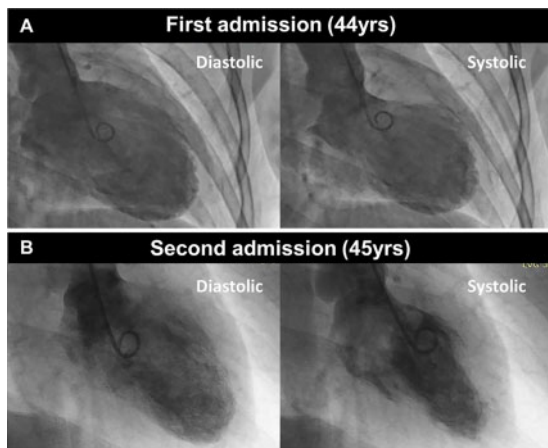


Figure 2 Left ventriculograms showing apical ballooning at the first admission (A) and basal ballooning at the second admission (B).

shown in [Figure 3](#), intracoronary administration of ACh (20, 50, and 100 μg) into the left coronary artery (LCA) and that of ACh (25 and 50 μg) into the right coronary artery induced epicardial coronary spasm accompanied by chest pain and ischaemic ECG changes. Chest pain, ischaemic ECG changes, and myocardial lactate production⁷ were already noted at the timing of administration of 20 μg of ACh into the LCA before the occurrence of epicardial coronary spasm at 100 μg , indicating that microvascular spasm (MVS) preceded epicardial coronary spasm. Thus, we diagnosed that she had both epicardial coronary spasm and MVS, and initiated drug therapy with a calcium antagonist (benidipine 8 mg/day). After discharge from our hospital, she experienced no episode of postprandial attacks and her urinary catecholamine levels remained low, indicating that she was free of catecholamine surges from pheochromocytoma ([Table 1](#)). She again underwent a scheduled follow-up ACh provocation testing at 18 months after the

operation. Calcium antagonist was discontinued 72 h before the provocation testing. Interestingly, epicardial coronary spasm was no longer induced, whereas MVS persisted ([Figure 3](#)).

Discussion

To the best of our knowledge, this is the first documented case of recurrent takotsubo-like cardiomyopathy associated with pheochromocytoma exhibiting different patterns of LV wall motion abnormality and coronary vasospasm. Pheochromocytoma is a rare neuroendocrine catecholamine-secreting tumour that arises from chromaffin tissue of the sympathetic nervous system, with an annual incidence of $\sim 0.8/100\,000$ person-year.⁸ Clinical manifestation of pheochromocytoma is highly variable. Indeed, this case had chest symptoms (e.g. dyspnoea and pain) and paroxysmal neck swelling after meals. Paroxysmal thyroid swelling in pheochromocytoma, first described in 1937,⁹ is caused by multiple oedemas associated with increased blood flow generally mediated by norepinephrine surges.¹⁰ Actually, the pheochromocytoma of this case was pathologically diagnosed as a norepinephrine-secreting type. Thus, her repeated paroxysmal thyroid swellings after meals reflected common occurrence of norepinephrine surge in daily life. Furthermore, it was reported that such frequent norepinephrine surges could give rise to different clinical manifestations and increased complications in patients with Pheo-TTS as compared with primary-TTS.^{3,4} In a previous retrospective study of 80 Pheo-TTS cases, $\sim 1/3$ patients had basal or inverted pattern and 1/5 had diffuse pattern,⁴ whereas $>80\%$ of primary-TTS patients showed apical LV dysfunction pattern.¹¹ Furthermore, the recurrence rate of TTS was 17.7% in the Pheo-TTS population,⁴ which was relatively higher as compared with that in primary-TTS patients ($<5\%$).¹¹ Nevertheless, this case is important as Pheo-TTS developed three times with different patterns of LV wall motion abnormality each time. Long-term and intermittent exposure to supraphysiological levels of catecholamines in Pheo-TTS patients could change densities of β_1 -adrenoreceptors in the myocardium¹² and also could trigger intracellular signal-trafficking from Gs to Gi protein signalling in the β_2 -adrenoceptor coupling, resulting in negative inotropic response.¹³ Thus, temporal change in the density of myocardial β_1 - and β_2 -adrenoreceptors could have contributed to the different LV wall motion abnormal patterns in this case. Additionally, repetitive catecholamine surges could also cause coronary functional abnormalities. In fact, the first ACh provocation testing at the age of 45 was negative, whereas at the age of 50 just after the surgical removal of the tumour, the second ACh testing provoked both epicardial and microvascular coronary spasms. Interestingly, in the third ACh testing at 1.5 years after the operation, epicardial coronary spasm disappeared, and only MVS persisted. These results suggest a close relationship between recurrent norepinephrine surges and the extent of coronary functional abnormalities. Actually, neuro-sympathetic activation due to physical and mental stress has been found to induce coronary vasoconstriction and subsequent myocardial ischaemia, the degree of which well correlated with the response to ACh infusion.¹⁴ Furthermore, the present results are also consistent with the findings of previous studies that the extent of vasomotor dysfunction was greater in the microcirculation than in the epicardial coronary arteries and that demonstration of

Table 1 Daily urinary excretion of catecholamines

	Before operation (mg/day)	10 days after operation (mg/day)	1.5 years after operation (mg/day)	Normal range (mg/day)
Normetanephrine	0.51	0.14	0.10	0.10–0.28
Metanephrine	0.14	0.12	0.11	0.04–0.18
VMA	4.8	0.15	0.13	1.5–4.9

VMA, vanillylmandelic acid.

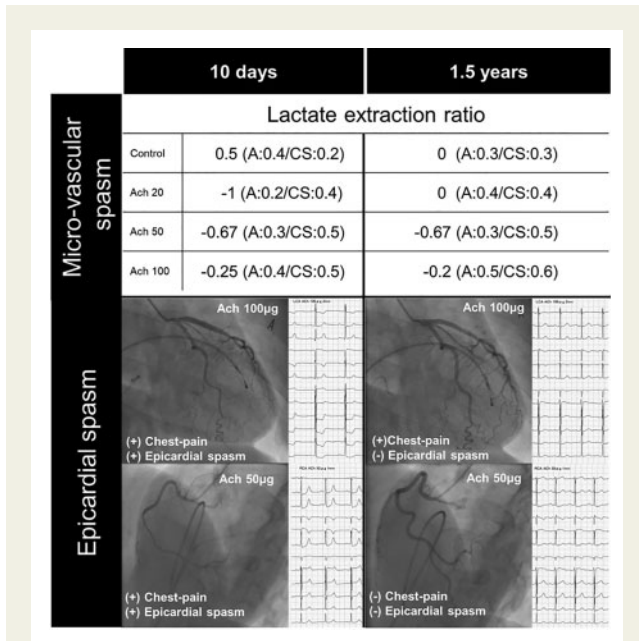


Figure 3 To evaluate the presence of microvascular spasm, we examined lactate production during acetylcholine provocation testing. At 1 min after each dose of acetylcholine was administered to LCA, paired samples of 1 mL of blood were collected from the left coronary ostium and the coronary sinus for measurement of lactate concentrations, which was immediately determined with a calibrated automatic lactate analyser (ABL8000 FLEX system, RADIOMETER, Copenhagen, Denmark). Myocardial lactate extraction ratio was calculated as the ratio of the coronary arterial-venous difference in lactate concentration to the arterial concentration. Myocardial lactate production defined by negative myocardial lactate extraction ratio is considered to be highly sensitive for myocardial ischaemia. We defined microvascular spasm as myocardial lactate production despite the absence of epicardial spasm throughout acetylcholine testing or prior to the occurrence of epicardial coronary spasm following intracoronary injections of acetylcholine. In acetylcholine testing performed just after the operation, both epicardial and microvascular spasm were induced. However, in acetylcholine testing at 1-year follow-up, epicardial spasm was no longer noted, whereas microvascular spasm persisted.

abnormal epicardial coronary vasoconstriction was more dependent on the timing of functional evaluation.¹⁵ This case also confirmed the importance of coronary functional disorders as a cause of different patterns of LV wall motion abnormality in TTS

patients.⁶ Since coronary dysfunction in Pheo-TTS patients could be reversible by removal of pheochromocytoma, it is important for clinicians to include pheochromocytoma in differential diagnosis of recurrent TTS.

Conclusions

This case indicates that intermittent norepinephrine surges due to pheochromocytoma may cause morphologically different types of transient LV wall motion abnormality, in which reversible coronary vasomotor dysfunction may be involved.

Lead author biography



Koichi Sato is a student of Department of Cardiovascular Medicine, Tohoku University Graduate School of Medicine, Sendai, Japan from 2016. He obtained a Japanese medical doctor's licence in 2014.

Supplementary material

Supplementary material is available at *European Heart Journal - Case Reports* online.

Slide sets: A fully edited slide set detailing this case and suitable for local presentation is available online as [Supplementary data](#).

Consent: The author/s confirm that written consent for submission and publication of this case report including image(s) and associated text has been obtained from the patient in line with COPE guidance.

Conflict of interest: none declared.

References

- Pelliccia F, Kaski JC, Crea F, Camici PG. Pathophysiology of takotsubo syndrome. *Circulation* 2017;**135**:2426–2441.
- Lenders JWM, Duh QY, Eisenhofer G, Gimenez-Roqueplo AP, Grebe SKG, Murad MH, Naruse M, Pacak K, Young WF. Pheochromocytoma and

- paranglioma: an endocrine society clinical practice guideline. *J Clin Endocrinol Metab* 2014;**99**:1915–1942.
3. Agarwal V, Kant G, Hans N, Messerli FH. Takotsubo-like cardiomyopathy in pheochromocytoma. *Int J Cardiol* 2011;**153**:241–248.
 4. Y-Hassan S. Clinical features and outcome of pheochromocytoma-induced takotsubo syndrome: analysis of 80 published cases. *Am J Cardiol* 2016;**117**:1836–1844.
 5. Kurisu S, Sato H, Kawagoe T, Ishihara M, Shimatani Y, Nishioka K, Kono Y, Umemura T, Nakamura S. Tako-tsubo-like left ventricular dysfunction with ST-segment elevation: A novel cardiac syndrome mimicking acute myocardial infarction. *Am Heart J* 2002;**143**:448–455.
 6. Verna E, Provasoli S, Ghiringhelli S, Morandi F, Salerno-Uriarte J. Abnormal coronary vasoreactivity in transient left ventricular apical ballooning (tako-tsubo) syndrome. *Int J Cardiol* 2018;**250**:4–10.
 7. Odaka Y, Takahashi J, Tsuburaya R, Nishimiya K, Hao K, Matsumoto Y, Ito K, Sakata Y, Miyata S, Manita D, Hirowatari Y, Shimokawa H. Plasma concentration of serotonin is a novel biomarker for coronary microvascular dysfunction in patients with suspected angina and unobstructive coronary arteries. *Eur Heart J* 2016;**38**:489–496.
 8. Lenders JWM, Eisenhofer G, Mannelli M, Pacak K. Pheochromocytoma. *Lancet* 2005;**366**:665–675.
 9. Howard JE, Barker WH. Paroxysmal hypertension and other clinical manifestation associated with benign chromaffin cell tumor (phaeochromocytoma). *Bull Johns Hopkins Hosp* 1937;**61**:371–410.
 10. Nakamura K, Ogata M, Ando T, Usa T, Kawakami A. Paroxysmal thyroid swelling. A forgotten clinical finding of pheochromocytoma. *J Clin Endocrinol Metab* 2011;**96**:3601–3602.
 11. Templin C, Ghadri JR, Diekmann J, Napp LC, Bataiosu DR, Jaguszewski M, Cammann VL, Sarcon A, Geyer V, Neumann CA, Seifert B, Hellermann J, Schwyzer M, Eisenhardt K, Jenewein J, Franke J, Katus HA, Burgdorf C, Schunkert H, Moeller C, Thiele H, Bauersachs J, Tschöpe C, Schultheiss H-P, Laney CA, Rajan L, Michels G, Pfister R, Ukena C, Böhm M, Erbel R, Cuneo A, Kuck K-H, Jacobshagen C, Hasenfuss G, Karakas M, Koenig W, Rottbauer W, Said SM, Braun-Dullaeus RC, Cuculi F, Banning A, Fischer TA, Vasankari T, Airaksinen KEJ, Fijalkowski M, Rynkiewicz A, Pawlak M, Opolski G, Dworakowski R, MacCarthy P, Kaiser C, Osswald S, Galiuto L, Crea F, Dichtl W, Franz WM, Empen K, Felix SB, Delmas C, Lairez O, Erne P, Bax JJ, Ford I, Ruschitzka F, Prasad A, Lüscher TF. Clinical features and outcomes of takotsubo (stress) cardiomyopathy. *N Engl J Med* 2015;**373**:929–938.
 12. Snavely MD, Mahan LC, O'Connor DT, Insel PA. Selective down-regulation of adrenergic receptor subtypes in tissues from rats with pheochromocytoma. *Endocrinology* 1983;**113**:354–361.
 13. Paur H, Wright PT, Sikkil MB, Tranter MH, Mansfield C, O'Gara P, Stuckey DJ, Nikolaev VO, Diakonov I, Pannell L, Gong H, Sun H, Peters NS, Petrou M, Zheng Z, Gorelik J, Lyon AR, Harding SE. High levels of circulating epinephrine trigger apical cardiodepression in a β_2 -adrenergic receptor/Gi-dependent manner: a new model of takotsubo cardiomyopathy. *Circulation* 2012;**126**:697–706.
 14. Yeung AC, Vekshtein VI, Krantz DS, Vita JA, Ryan TJ Jr, Ganz P, Selwyn AP. The effect of atherosclerosis on the vasomotor response of coronary arteries to mental stress. *N Engl J Med* 1991;**325**:1551–1556.
 15. Patel SM, Lerman A, Lennon RJ, Prasad A. Impaired coronary microvascular reactivity in women with apical ballooning syndrome (takotsubo/stress cardiomyopathy). *Eur Heart J Acute Cardiovasc Care* 2013;**2**:147–152.