

Beneficial Effects of Imatinib in a Patient with Suspected Pulmonary Veno-Occlusive Disease

Haruka Sato,¹ Koichiro Sugimura,¹ Masanobu Miura,¹ Ryo Konno,¹ Katsuya Kozu,¹ Nobuhiro Yaoita,¹ Toru Shimizu,¹ Saori Yamamoto,¹ Tatsuo Aoki,¹ Shunsuke Tatebe,¹ Kimio Satoh¹ and Hiroaki Shimokawa¹

¹Department of Cardiovascular Medicine, Tohoku University Graduate School of Medicine, Sendai, Miyagi, Japan

Pulmonary veno-occlusive disease (PVOD) is a rare form of pulmonary hypertension (PH). The prognosis of PVOD patients remains poor, since no effective medical therapy is yet available. Imatinib is a tyrosine kinase inhibitor specific for platelet-derived growth factor receptor and is expected as a treatment option for pulmonary arterial hypertension (PAH). Recently, it has been reported that imatinib improved functional capacity of a patient with PVOD. We here report a patient with suspected PVOD who has been successfully treated with imatinib and is alive for 6 years after diagnosis. A 57-year-old woman was admitted to a hospital for severe dyspnea. Echocardiography suggested the presence of PH, because tricuspid regurgitation pressure gradient was elevated. The patient was then transferred to our hospital by an ambulance ahead of schedule due to fever and worsening dyspnea. Because the patient had no left heart disease, we diagnosed that she had PAH associated with severe right heart failure. We immediately started treatment with nitric oxide (NO) for her severe hypoxia; however, it caused pulmonary edema. We suspected PVOD from CT characteristics and pulmonary edema after PAH-targeted vasodilator therapy, and then started oral imatinib treatment. In response to imatinib, her pulmonary edema gradually improved. Since then, the patient has been alive for 6 years with imatinib and pulmonary vasodilators. At present, lung transplantation is the only effective therapy for PVOD with limited availability. We therefore propose that imatinib may be a treatment option for PVOD and a bridge to lung transplantation.

Keywords: imatinib; pulmonary arterial hypertension; pulmonary hypertension; pulmonary veno-occlusive disease; transplantation

Tohoku J. Exp. Med., 2019 February, 247 (2), 69-73. © 2019 Tohoku University Medical Press

Introduction

Pulmonary veno-occlusive disease (PVOD) is a rare cause of pulmonary hypertension (PH), and is a life-threatening disease characterized by elevated pulmonary arterial pressure. PH is defined as increased mean pulmonary arterial pressure (mPAP) ≥ 25 mmHg and pulmonary vascular residence (PVR) ≥ 3.0 wood units (WU) at rest as assessed by right heart catheterization (RHC). Pulmonary arterial hypertension (PAH) is defined when pulmonary capillary wedge pressure (PCWP) < 15 mmHg (Galiè et al. 2016), and is classified as Group 1 at 5th World Symposium on Pulmonary Hypertension (2013). While PAH is characterized by pulmonary arterial obstruction, PVOD by pulmonary veins obstruction. Since PVOD shows similar hemodynamics as PAH, it is classified as Group 1'. We diagnose PVOD from combination of clinical suspicion, physical examination and radiological findings, based on 2015 ESC/ERS guidelines of pulmonary hypertension (Galiè et al.

2016).

The prognosis of PVOD remains poor as no effective medical therapy is yet available for the disorder (Montani et al. 2016). Imatinib is a tyrosine kinase inhibitor specific for platelet-derived growth factor receptor (PDGFR) (Capdeville et al. 2002). Since PDGFR is highly expressed in smooth muscle cell of pulmonary artery of patients with PAH (Perros et al. 2008), imatinib is expected as a treatment option for PAH patient (Ghofrani et al. 2005). However, imatinib failed to be a treatment option in the phase III trial because of the adverse events despite its efficacy (Hoepfer et al. 2013). Recently it has been reported that imatinib could improve functional capacity in PVOD patients who were clinically diagnosed, although in some cases the diagnosis is made only pathologically after autopsy or lung transplantation (Overbeek et al. 2008; Ogawa et al. 2017).

We here report a patient with suspected PVOD who was successfully treated with imatinib and is alive for 6

Received September 10, 2018; revised and accepted January 9, 2019. Published online January 30, 2019; doi: 10.1620/tjem.247.69.

Correspondence: Koichiro Sugimura, M.D., Ph.D., Department of Cardiovascular Medicine, Tohoku University Graduate School of Medicine, 1-1 Seiryō-machi, Aoba-ku, Sendai, Miyagi 980-8574, Japan.
e-mail: ksugimura@cardio.med.tohoku.ac.jp

years after diagnosis.

Case Report

A 57-year-old woman who did not smoke and had no previous medical history was admitted to a hospital for severe dyspnea. Echocardiography showed elevated tricuspid regurgitation pressure gradient (TRPG), suggesting the presence of PH. The patient was then transferred to our hospital by an ambulance ahead of schedule, due to fever and worsened dyspnea. She was in WHO functional class (WHO-FC) IV. Her blood pressure was 106/70 mmHg, body temperature 38.2°C, and oxygen saturation 96% with 7 L/min O₂ with oxygen mask. Blood gas analysis also showed hypoxia with PaO₂ 81.6 mmHg with 5 L/min O₂ with oxygen mask. Serum brain natriuretic peptide (BNP) levels were elevated (900.3 pg/mL). None of autoimmune serology tests was positive. Electrocardiogram showed down-sloping ST depression in leads II, III and aVf and negative T in leads V1 to V4. Echocardiography showed dilated right ventricle (38 mm at end-diastole) with TRPG of 95 mmHg. Chest X-ray showed cardiomegaly and pulmonary congestion (Fig. 1A). A high-resolution computed tomography (hrCT) scan revealed mosaic ground-glass opacities (GGO), thickened septal lines, and mediastinal lymphadenopathy (Fig. 1B, C).

The patient was diagnosed as having PH associated with severe right heart failure. There was no evidence of left heart disease or lung disease. We first considered that she had PAH and that her right heart failure was caused by fever. Thus, we started to treat her with inhaled nitric oxide (NO). After 15 min, her dyspnea transiently improved with decreased TRPG to 57 mmHg. However, one hour after starting inhaled NO, her dyspnea and hypoxemia became progressively worsened, and we urgently treated her with a mechanical respiratory support. Importantly, chest X-ray showed severe pulmonary congestion (Fig. 1D). Based on the development of pulmonary edema after vasodilator therapy and the hrCT findings of mosaic GGO, thickened septal lines, and mediastinal lymphadenopathy, we finally suspected that the patient had PVOD. Since inhaled NO therapy had caused pulmonary edema, we immediately stopped the NO therapy.

Based on the previous report (Overbeek et al. 2008), we started the treatment with oral imatinib at a dose of 200 mg daily. After 2 days, chest X-ray showed improvement of pulmonary congestion, and after one week, we were able to successfully discontinue mechanical respiratory support. The patient's DLCO (50.9%) was slightly lower of the predicted value. RHC revealed mPAP of 48 mmHg, PCWP 9 mmHg, and PVR 10.7 WU (Normal range: mPAP 9-18 mmHg, PVR < 3.0 WU). These hemodynamic conditions suggested that while occlusion of pulmonary vein might have improved, constriction of pulmonary arteries remained, and then RHC showed precapillary PH. We thus decided to continue the treatment with imatinib, which resulted in further improvement of dyspnea and reduced

mean PAP (42 mmHg) and PVR (6.6 WU). We also carefully added pulmonary vasodilators (sildenafil, ambrisentan, and beraprost). At 9 months after the combination therapy with imatinib and pulmonary vasodilators, mean PAP and PVR were further improved to 41 mmHg and 4.9 WU, respectively, and hrCT showed the improvement of mosaic ground-glass opacities and thickened septal lines (Fig. 1E). Since then, 6 years have passed, and the patient is now in WHO-FC II, and recent RHC showed that she has mPAP 33 mmHg and PVR 3.3 WU. under the treatment with imatinib and pulmonary vasodilators. We continue the treatment with imatinib under the approval from the ethics committee of Tohoku University Hospital (#2015-2-214).

Discussion

At present, lung transplantation is the only proven effective treatment of PVOD (Montani et al. 2016). However, the present patient was not suitable for lung transplantation because of her elderly age. The patient has been alive for 6 years since her first admission under the treatment with imatinib and pulmonary vasodilators. To the best of our knowledge, our patient is the longest survival case of PVOD with imatinib and vasodilators.

PVOD is a rare form of PH, accounting for ~10% of patients with idiopathic PAH (Mandel et al. 2000). It was previously reported that one-year mortality rate was 72% (Holcomb et al. 2000) with the mean time from diagnosis to death of 14.3 months and that from first symptom to death of 24.7 months (Montani et al. 2008). Since all pulmonary vasodilators, including epoprostenol, have failed to achieve hemodynamic improvement or long-term survival in PVOD (Montani et al. 2009), lung transplantation is the only definitive therapy for the disorder (Montani et al. 2016). However, limited availability of lung transplantation is an important problem in Japan and abroad (Wille et al. 2014).

Since PVOD and PAH share similar clinical presentations, such as insidious onset of fatigue, breathlessness progressing to right heart failure, and hemodynamics of high pulmonary arterial pressure, it is practically difficult to differentiate them in the clinical setting. However, pathological presentations are different and useful; PVOD is characterized by fibrous narrowing and obstruction of small pulmonary veins, while PAH by small pulmonary artery lesions (Holcomb et al. 2000; Montani et al. 2008). To make an accurate diagnosis of PVOD, lung biopsy is needed; however, it is a high-risk procedure for PAH patients (McGoon et al. 2004). Furthermore, vasodilator therapy for PAH causes pulmonary edema in PVOD patients because pulmonary arterioles dilate with resultant increase in transcapillary hydrostatic pressure due to pulmonary vein obstruction (Dai and Matsui 2014). Thus, in addition to CT findings, such as thickening of interlobular septa and lymphadenopathy, pulmonary edema after vasodilator therapy was highly suggestive of PVOD in our case (Galiè et al. 2016). Before treatment with pulmonary vasodilators, the presence of abnormalities on hrCT is also sug-

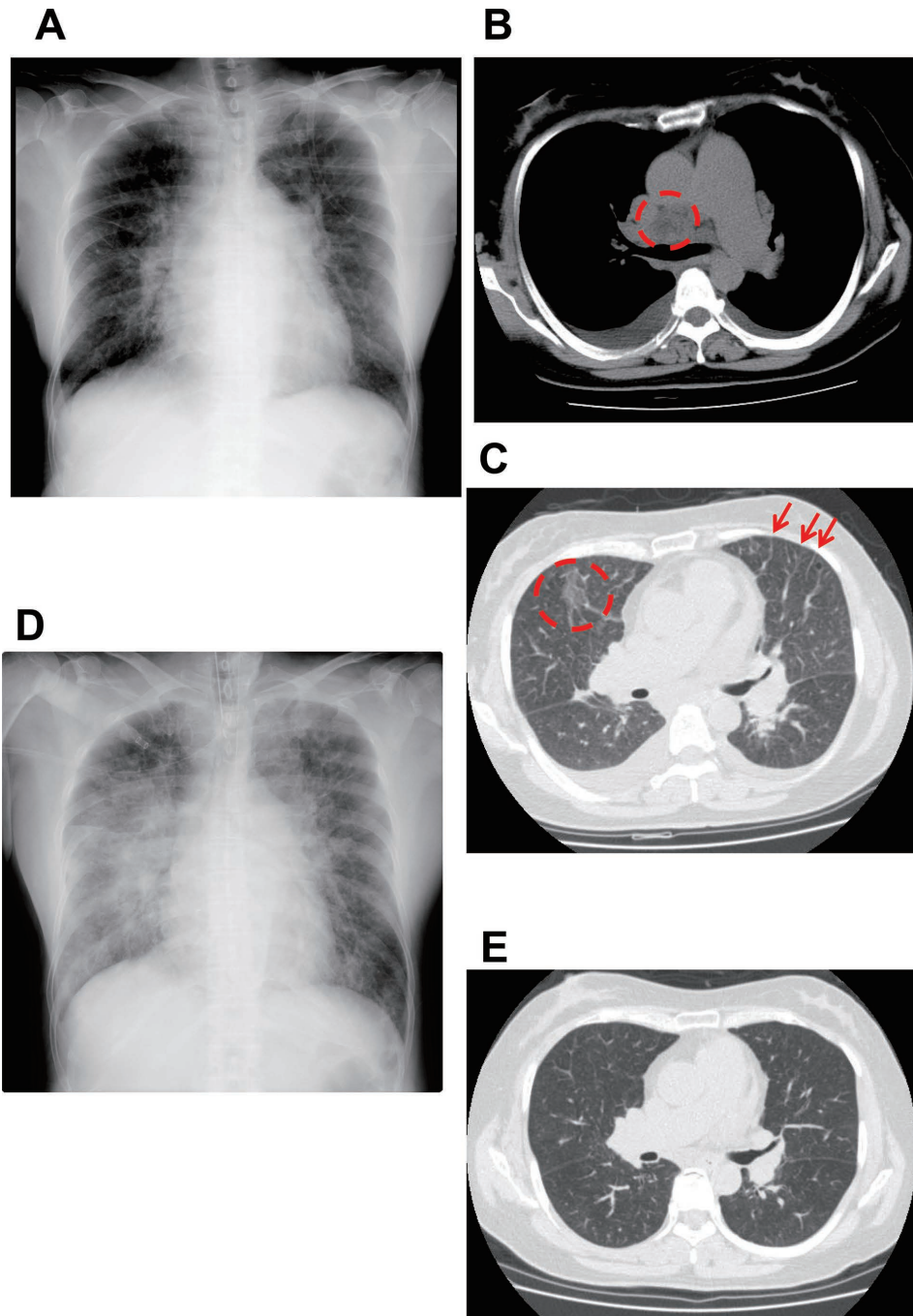


Fig. 1. Chest X-rays and CT images.

- (A) Chest X-ray on admission.
- (B) High-resolution computed tomography showing mediastinal lymphadenopathy (circle).
- (C) High-resolution computed tomography showing mosaic ground-glass opacities (circle) and thickened septal lines (arrows).
- (D) Chest X-ray after pulmonary vasodilator therapy showing pulmonary congestion.
- (E) High-resolution computed tomography after imatinib therapy showing the disappearance of ground-glass opacities and thickened septal lines.

gestive of PVOD (Dai and Matsui 2014; Montani et al. 2016).

Imatinib is a tyrosine kinase inhibitor specific for PDGFR, which is highly expressed in pulmonary arteries in PAH patients and considered one of the exacerbating fac-

tors of the disorder. Since imatinib was initially expected as a treatment option for PAH (Ghofrani et al. 2005; Schermuly et al. 2005), the IMPRES Study was performed as a global phase III trial in 2009 to 2011. However, this trial failed because of the adverse events including subdural

hematoma, despite its efficacy for improving exercise capacity and hemodynamics (Hoepfer et al. 2013).

Overbeek et al. (2008) reported for the first time the effectiveness of imatinib for PVOD. Later, in 2011, they also reported that PDGF was upregulated in the pulmonary nodules of PVOD patients (Overbeek et al. 2011). In contrast, Koiwa et al. (2011) reported a refractory case of PVOD to imatinib, in which case PDGFR was not expressed in the pulmonary veins. These results suggest that imatinib may be effective for PVOD patients whose pulmonary veins expressed PDGF. In our institute, 6 patients were diagnosed as having PVOD from 2004 to 2017. In our department, we make the diagnosis of PVOD based on the clinical history, hrCT, and/or histology (Dai and Matsui 2014; Montani et al. 2016) plus desaturation or pulmonary edema after treatment with pulmonary vasodilators, and CT findings, such as ground-glass opacities, thickened septal lines, and mediastinal lymphadenopathy. Among them, 4 patients died, one underwent lung transplantation, and the remaining one, the present case, is alive with imatinib for 6 years. Pathological examination showed that the patient who underwent transplantation had intimal fibrosis and obstruction of pulmonary veins. In our institute, the mean time from presentation to death was 16.5 months, a consistent finding with the previous reports (Holcomb et al. 2000; Montani et al. 2008). The present patient is alive for 6 years without heart failure or hospitalization with oral administration of imatinib and pulmonary vasodilators. To the best of our knowledge, she is the longest-surviving PVOD patient. Imatinib may work as a bridge to lung transplantation, which is important in Japan where waiting time is more than 3 years.

Although we were initially unable to use pulmonary vasodilators because of pulmonary edema, we were then able to add the vasodilators with imatinib, which suggests that the PDGFR inhibitor dilated her pulmonary veins. Schermuly et al. (2005) reported that treatment with imatinib for 2 weeks resulted in significant reduction in fully muscularized arteries and reversed the increase in medial wall thickness in rats with monocrotaline-induced pulmonary hypertension. Indeed, in PVOD, medial hypertrophy and intimal fibrosis may be present not only in veins but also in small arteries (Montani et al. 2016). Thus, we needed imatinib, followed by pulmonary vasodilators.

In summary, considering the present case, we suggest that imatinib is a useful treatment option for PVOD.

Conflict of Interest

The authors declare no conflict of interest.

References

- Capdeville, R., Buchdunger, E., Zimmermann, J. & Matter, A. (2002) Glivec (STI571, imatinib), a rationally developed, targeted anticancer drug. *Nat. Rev. Drug Discov.*, **1**, 493-502.
- Dai, Z. & Matsui, Y. (2014) Pulmonary veno-occlusive disease: an 80-year-old mystery. *Respiration*, **88**, 148-157.
- Galiè, N., Humbert, M., Vachiery, J.L., Gibbs, S., Lang, I., Torbicki, A., Simonneau, G., Peacock, A., Vonk Noordegraaf, A., Beghetti, M., Ghofrani, A., Gomez Sanchez, M.A., Hansmann, G., Klepetko, W., Lancellotti, P., et al. (2016) 2015 ESC/ERS Guidelines for the diagnosis and treatment of pulmonary hypertension: the joint task force for the diagnosis and treatment of pulmonary hypertension of the European Society of Cardiology (ESC) and the European Respiratory Society (ERS): endorsed by: Association for European Paediatric and Congenital Cardiology (AEPC), International Society for Heart and Lung Transplantation (ISHLT). *Eur. Heart J.*, **37**, 67-119.
- Ghofrani, H.A., Seeger, W. & Grimminger, F. (2005) Imatinib for the treatment of pulmonary arterial hypertension. *N. Engl. J. Med.*, **353**, 1412-1413.
- Hoepfer, M.M., Barst, R.J., Bourge, R.C., Feldman, J., Frost, A.E., Galie, N., Gomez-Sanchez, M.A., Grimminger, F., Grunig, E., Hassoun, P.M., Morrell, N.W., Peacock, A.J., Satoh, T., Simonneau, G., Tapson, V.F., et al. (2013) Imatinib mesylate as add-on therapy for pulmonary arterial hypertension: results of the randomized IMPRES study. *Circulation*, **127**, 1128-1138.
- Holcomb, B.W. Jr., Loyd, J.E., Ely, E.W., Johnson, J. & Robbins, I.M. (2000) Pulmonary veno-occlusive disease: a case series and new observations. *Chest*, **118**, 1671-1679.
- Koiwa, H., Tsujino, I., Ikeda, D., Ohira, H., Tanino, M. & Nishimura, M. (2011) An autopsy case of pulmonary veno-occlusive disease refractory to imatinib. *Eur. Respir. J.*, **37**, 968-970.
- Mandel, J., Mark, E.J. & Hales, C.A. (2000) Pulmonary veno-occlusive disease. *Am. J. Respir. Crit. Care Med.*, **162**, 1964-1973.
- McGoon, M., Gutterman, D., Steen, V., Barst, R., McCrory, D.C., Fortin, T.A. & Loyd, J.E.; American College of Chest Physicians (2004) Screening, early detection, and diagnosis of pulmonary arterial hypertension: ACCP evidence-based clinical practice guidelines. *Chest*, **126**, 14S-34S.
- Montani, D., Achouh, L., Dorfmueller, P., Le Pavec, J., Szymf, B., Tcherakian, C., Rabiller, A., Haque, R., Sitbon, O., Jais, X., Darteville, P., Maitre, S., Capron, F., Musset, D., Simonneau, G., et al. (2008) Pulmonary veno-occlusive disease: clinical, functional, radiologic, and hemodynamic characteristics and outcome of 24 cases confirmed by histology. *Medicine (Baltimore)*, **87**, 220-233.
- Montani, D., Jais, X., Price, L.C., Achouh, L., Degano, B., Mercier, O., Mussot, S., Fadel, E., Darteville, P., Sitbon, O., Simonneau, G. & Humbert, M. (2009) Cautious epoprostenol therapy is a safe bridge to lung transplantation in pulmonary veno-occlusive disease. *Eur. Respir. J.*, **34**, 1348-1356.
- Montani, D., Lau, E.M., Dorfmueller, P., Girerd, B., Jais, X., Savale, L., Perros, F., Nossent, E., Garcia, G., Parent, F., Fadel, E., Soubrier, F., Sitbon, O., Simonneau, G. & Humbert, M. (2016) Pulmonary veno-occlusive disease. *Eur. Respir. J.*, **47**, 1518-1534.
- Ogawa, A., Miyaji, K. & Matsubara, H. (2017) Efficacy and safety of long-term imatinib therapy for patients with pulmonary veno-occlusive disease and pulmonary capillary hemangiomas. *Respir. Med.*, **131**, 215-219.
- Overbeek, M.J., Boonstra, A., Voskuyl, A.E., Vonk, M.C., Vonk-Noordegraaf, A., van Berkel, M.P., Mooi, W.J., Dijkmans, B.A., Hondema, L.S., Smit, E.F. & Grunberg, K. (2011) Platelet-derived growth factor receptor-beta and epidermal growth factor receptor in pulmonary vasculature of systemic sclerosis-associated pulmonary arterial hypertension versus idiopathic pulmonary arterial hypertension and pulmonary veno-occlusive disease: a case-control study. *Arthritis Res. Ther.*, **13**, R61.
- Overbeek, M.J., van Nieuw Amerongen, G.P., Boonstra, A., Smit, E.F. & Vonk-Noordegraaf, A. (2008) Possible role of imatinib

- in clinical pulmonary veno-occlusive disease. *Eur. Respir. J.*, **32**, 232-235.
- Perros, F., Montani, D., Dorfmüller, P., Durand-Gasselin, I., Tcherakian, C., Le Pavec, J., Mazmanian, M., Fadel, E., Mussot, S., Mercier, O., Herve, P., Emilie, D., Eddahibi, S., Simonneau, G., Souza, R., et al. (2008) Platelet-derived growth factor expression and function in idiopathic pulmonary arterial hypertension. *Am. J. Respir. Crit. Care Med.*, **178**, 81-88.
- Schermuly, R.T., Dony, E., Ghofrani, H.A., Pullamsetti, S., Savai, R., Roth, M., Sydykov, A., Lai, Y.J., Weissmann, N., Seeger, W. & Grimminger, F. (2005) Reversal of experimental pulmonary hypertension by PDGF inhibition. *J. Clin. Invest.*, **115**, 2811-2821.
- Wille, K.M., Sharma, N.S., Kulkarni, T., Lammi, M.R., Barney, J.B., Bellot, S.C., Cantor, R.S., Naftel, D.C., Diaz-Guzman, E. & McGiffin, D.C. (2014) Characteristics of patients with pulmonary venoocclusive disease awaiting transplantation. *Ann. Am. Thorac. Soc.*, **11**, 1411-1418.
-